JOURNAL OF THE CARIBBEAN COLLEGE OF SURGEONS

JCCS; 2021; VOL 2

MEDICAL ASSOCIATES HOSPITAL

EXCELLENCE IN MEDICAL CARE

State of the art Surgical Equipment to allow Surgeons to perform Open & Minimally Invasive Procedures in a Multi-Disciplinary Organization.

At **Medical Associates** we perform:

- Vascular Surgery (Carotid, Aortic, Lower Limb)
- Advanced Vascular Access
- Endovascular Surgery
- ERCP, MRCP
- Breast Conservation Surgery
- Oncoplastic Breast Surgery
- Breast Reconstructive Surgery
- Laser Lithotripsy
- Laser Prostatectomy

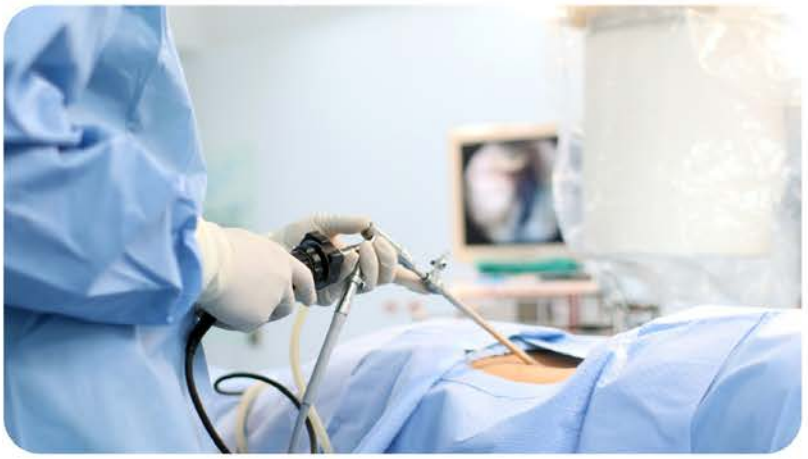

Inclusive of that, we also perform Laparoscopic Surgeries which includes:

- Oesophagectomy
- Pancreatectomy
- Colon Cancer
- Rectal Cancer
- Appendicectomy
- Splenectomy
- Gastric Cancer
- Cholecystectomy
- CBD Exploration
- Sleeve Gastrectomy & Bypass
- Diagnostic Laparoscopy
- Staging Laparoscopy & Biopsies

Medical
ASSOCIATES
Hospital

Full Range Radiology Equipment to assist with Diagnosis & Patient Management.

Feel Free to Contact us to discuss working with
Our Team of Esteemed Surgeons.
Tel: 1.868.662.2766
www.medicalassociatestt.info

Official Journal of the
Caribbean College of Surgeons

Editorial Committee:

Chief Editor	Prof. Shamir Cawich	Trinidad & Tobago
Deputy Editor	Dr. Wesley Francis	Bahamas
Deputy Editor	Prof. Vijay Naraynsingh	Trinidad & Tobago
Deputy Editor	Dr. Lindberg Simpson	Jamaica

Associate Editors:

Dr. Bill Aiken	Jamaica
Dr. Ian Bambury	Jamaica
Dr. Brian Brady	Trinidad & Tobago
Dr. Charlie Greenidge	St. Lucia
Dr. Sahle Griffith	Barbados
Dr. Milton Harry	Jamaica
Dr. Marlon Mencia	Trinidad & Tobago
Dr. Margaret Oshea	Barbados
Dr. Shilindra Rajkumar	Guyana
Dr. Trevor Seepaul	Trinidad & Tobago
Dr. Yardesh Singh	Trinidad & Tobago
Dr. Alan Smith	Barbados
Dr. Myrton Smith	Jamaica
Dr. Eric Williams	Jamaica
Dr. Carlos Wilson	Jamaica

Advisory Board:

Dr. Terry Ali	Trinidad & Tobago
Prof. Ivor Crandon	Jamaica
Prof. Dilip Dan	Trinidad & Tobago
Dr. Patrick FaSiOen	Curacao
Dr. Ramesh Jonnalagadda	Barbados
Prof. Michael McFarlane	Jamaica
Dr. Gordon Naraynsingh	Trinidad & Tobago
Prof. Joseph Plummer	Jamaica
Prof Sir Errol Walrond	Barbados
Dr. Cameron Wilkinson	St. Kitts & Nevis

Published by:
OUT SOURZE IT
Hugh Ferreira- C: 868-788-9202
E: outsourzeit.hlf@gmail.com.

MSD
INVENTING FOR LIFE

CONFIDENCE COMES FULL CIRCLE

Tri-Staple™ technology is now on the EEA™ circular stapler

30% additional security to the staple lines[1-3,§,Ω,††]

Better audible and tactile feedback[4,†,‡]

Requires 14 percent less firing force[5,†]

Pending 510(k) not available for sale in the United States.

GREATER PERFUSION

May be allowed into the staple line compared to two row staplers[6,7,‡]

LESS STRESS

On tissue during compression and clamping compared to two row staplers[8,‡,††]

CONSISTENT PERFORMANCE

Over a broad range of tissue thicknesses compared to two row staplers[9-11]

1. Based on internal test report #2128-194. Comparison of EEA™ circular stapler with Tri-Staple™ technology to EEA™ circular stapler with DST Series™ technology in colorectal and gastrojejunal anastomoses. Aug. 20, 2013.
2. Based on internal test report #RE0035707. Pilot comparison of EEA™ circular stapler with Tri-Staple™ technology to EEA™ circular stapler with DST Series™ technology in an esophago-gastrostomy using a canine model. Feb. 25, 2015.
3. Based on internal test report #2128-097. Evaluation of early wound healing events in gastrojejunostomies and colonic anastomoses using a three row EEA™ stapler in canines. Aug. 7, 2013.
4. Based on internal test report #RE00073061. Tulip formative evaluation summary.
5. Based on internal test report #RE00074556. Tulip and DST firing force comparison report.
6. Based on internal test report #PCG-007. Media absorbency under clamped conditions. Aug. 9, 2012.
7. Based on colorectal perfusion studies performed for Endo GIA™ with Tri-Staple™ technology. Internal test report #2128-002-2. Final analysis of staple line vascularity using MicroCT. April 27, 2015.
8. Based on internal test report #PCG-30. Comparison of circular staplers: tissue compression profiles as determined by 2-D static axisymmetric finite element analysis (FEA).
9. Based on internal test report #RE00069039. EEA™ circular stapler with Tri-Staple™ technology design verification report. Dec. 2, 2014.
10. Based on internal test report #RE00080350. Tulip benchmark test report.
11. Based on internal test report #2128-053. Ethicon benchmark testing - Signa™ circular reload.
† As compared to two-row circular staplers.
‡ Preclinical results may not correlate with clinical performance in humans.
§ Based on the addition of a third row of staples in the EEA™ circular stapler with Tri-Staple™ technology, as compared to predicate two-row device designs.
Ω Refers to the healing period (generally through day 28) that was evaluated in multiple preclinical canine survival studies designed to assess device safety and efficacy.
†† Finite element analysis (FEA) was used to determine the strain profiles of three circular staplers during clamp-up: EEA™ circular stapler with Tri-Staple™ technology, EEA™ stapler with DST Series™ technology and Ethicon Endo-Surgery Circular Stapler. The EEA™ circular stapler with Tri-Staple™ technology demonstrated a broadened compression profile upon clamping.

© 2017 Medtronic. All rights reserved. Medtronic, Medtronic logo and Further. Together are trademarks of Medtronic. All other brands are trademarks of a Medtronic company. 11/2017-US170586(1)-[WF#2070526]

Medtronic
Further. Together

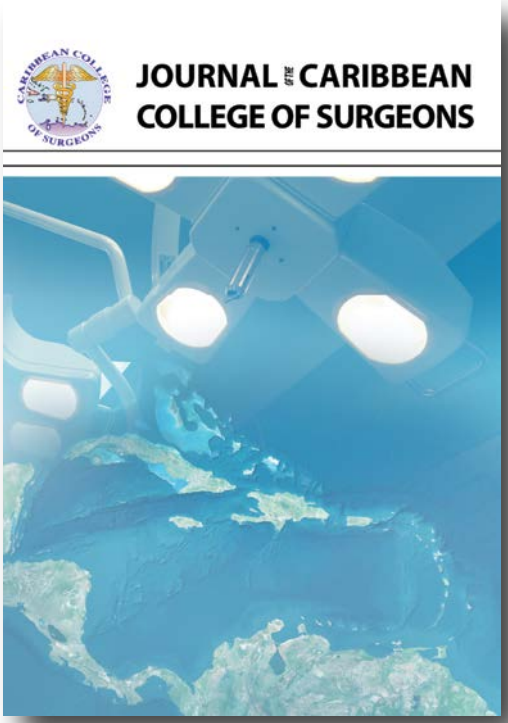

COVER DESIGN

The cover design for the Journal of the Caribbean College of Surgeons depicts a satellite image of the Caribbean region taken from space. The image shows the tranquil beauty of the region on the background of the aqua blue Caribbean Sea.

Although, the Caribbean is relatively small, it casts a large footprint that can be seen far and wide.

The cover also shows the surgical main and satellite lights that we use on a daily basis to illuminate the work that surgeons do. The emblem of the Caribbean College of Surgeons is featured in the top left hand corner, bringing together the qualities of the Caribbean and the work of the surgeons.

The cover was designed by our President, Dr. Cameron Wilkinson, and medical students from the Windsor Medical School, Omair Janjua and Shruti Patel.

PRESIDENT'S MESSAGE

Journal of the Caribbean College of Surgeons:
President's Message
Cameron Wilkinson

The Caribbean College of Surgeons continues with its vision set out 18 years ago in providing fellowship for its members, encouraging research and providing opportunities through which this research and surgical experiences can be presented to members and the international community.

We have continued to expand our foot print not just throughout the Caribbean but internationally. I had the opportunity to be present when the College was officially launched at the Kapok Hotel, Port of Spain Trinidad, in June 2003 and was elected to serve as a committee member under our first President Sir E.R Walrond.

This message now is bitter sweet for me as it causes me to reflect on how the College and its membership has grown over those few years and the knowledge gained and the great fellowship had at our annual meetings.

This is also my last message as President as my term comes to an end having served you for the last four years. I would first like to thank who prepared scientific presentations for our annual Caribbean College of Surgeons Conference, with the high standard that we have come to anticipate that truly enriches our annual experience.

We all anxiously await your delivery. I also want to thank all who contributed scientific papers and research to this edition, 2021 Volume 2, of the Caribbean College of Surgeons Journal. Your outstanding work will be forever etched across its pages for all now and in the future to see. I also want to thank all the Executive, Council and Committee members and fellows of the college for your sterling contribution to the college's success.

The Executive Council took the decision to shift our scientific conference to an online event a year ago because of the current COVID-19 pandemic. We have had a long and arduous battle with this virus.

We will continue to fight until we can see some light at the end of the tunnel, hopefully in the wake of achieving herd immunity through our various local vaccination programmes. We will certainly lose much of the camaraderie which has served to greatly enhance the social aspect of our annual meeting, but we are making the most of our current circumstances until we are able to physically meet again.

Despite these drawbacks, we look forward to a successful conference this month, and we anticipate our usual numbers. In our effort to maintain a seamless experience as we fully migrate to the digital world, we have employed the use of the online zoom platform, and have put the necessary measures in place to adequately accommodate this activity.

I take the opportunity now to thank you, the members for allowing me to lead this august body for the last four years. I have thoroughly enjoyed my journey especially in the spearheading of the College into the digital and social media world, thereby making it resilient and sustainable in the wake of the pandemic. I would also like to thank the Past Presidents who have played very important roles in the development of the college from its inception in 2003 to 2017 and who have supported me in my role as President.

We congratulate the following gentlemen on their individual contributions to its growth - Sir Errol Walrond (2003-2007), Prof Vijay Naraynsingh (2007-2011), Dr Deen Sharma (2011-2015) and Dr Ramesh Jonnalagadda (2015-2017).

Last, I now make room for our incoming President Prof Shamir Cawich and as I hand the mantle over to him, to continue in the development of the College, I wish him all the best in his endeavors and give him the assurance that I will be on hand to provide the same support the Immediate Past President and all my predecessors afforded me.

The future of the College looks great and it being placed in very capable hands.

I wish you a very successful virtual conference!

Dr. Cameron A. Wilkinson
C.B.E, C.S.M, MBBS, FACS, FCCS
President Caribbean College of Surgeons

EDITORS NOTE

19th Annual Caribbean College of Surgeons' Clinical Symposium

Shamir O Cawich

Author Details:

Prof. Shamir O Cawich, FCCOS
University of the West Indies
St Augustine Campus, Trinidad & Tobago
Email: socawich@hotmail.com

As the J.C.C.S. approaches the fifth year of publication, we are excited to see the overwhelming support from our members. This supplement publishes the abstracts of the 19th Annual Caribbean College of Surgeons' Clinical Symposium held on June 19 and 20, 2021.

This is always an eagerly anticipated event were our members meet in a Caribbean territory to share knowledge, data and experiences. Although this year's Annual Symposium is being held on a virtual platform, it has not diluted our enthusiasm. There has been overwhelming support from the fellows of the College, with contributions from many territories in the region.

We take this opportunity to thank the speakers who have spent many hours preparing their contributions as well as the members of the publication and steering committees. We hope that the J.C.C.S. continues to serve as a forum to share information that can impact surgical practice for the Caribbean.

Best regards,
Professor Shamir Cawich
Editor in Chief, Journal of the Caribbean College of Surgeons

CARIBBEAN COLLEGE OF SURGEONS

19th Annual
Clinical Conference

June 19-20, 2021

SATURDAY JUNE 19, 2021

Management of Oesophageal Perforations
Smith A
Barbados

Management of Mediastinal Malignancies
Coye A
Belize

COVID and Surgical Critical Care
Pust GD
Ryder Trauma Center/ Jackson Memorial Hospital, University of Miami

The Rate of Laparoscopic Conversions at Princess Margaret Hospital
Bodie D, Munroe LU
The Bahamas

Hidden Scar Appendectomy in Guyana
Singh D, Ramcharan H, Rambaran N
Guyana

Blindness Secondary to Optic Nerve Ischemia after Prolonged Cardiac Arrest
Pust GD, Kaslow A, Chatoor M, Jain S, Kateregga A, Ruiz G, Marttos A, Kaufman J, Hart V
USA

A Report of Chemodectoma
Shoogoon A, Pran L, Harnanan D
Trinidad & Tobago

Anterior Skull Based Trauma
Dixon B, Daley A, Goodluck-Tyndall R, Hall D, Holness R, Jadusingh W, Pencle FK
Jamaica

Penile Degloving Injury Secondary to Hair Torniquet
Dubay C, Rampersad B
Trinidad & Tobago

SUNDAY JUNE 20, 2021

Cutaneous Metastasis in Rectal Cancer post Abdomino perineal Resection and Pulmonary Metastasectomy
Johnson B, Ramlogan R, Moore I, Gamboa I, West M
Trinidad & Tobago

Knowledge of Breast Cancer in Patients Diagnosed with Breast Disease
Mohammed S, Islam S, Hosein A
Trinidad & Tobago

Primary Non-Cutaneous Malignant Melanoma of the Breast
Murray N, Hassranah D, Olivier L, DeFreitas A, Richardson R, Persad N
Trinidad & Tobago

Breast Carcinoma Receptor Expression in a Caribbean Population
Ramdass MJ, Gonzales J, Maharaj D, Simeon D, Barrow S
Trinidad & Tobago

An unusual cause of 'rectal prolapse'
Mohammed S, Singh Y, Hosein A, Naryansingh V
Trinidad & Tobago

Clinicopathologic Profile of Rectal Cancer in a Caribbean Hospital
Sirjeusingh D, Persaud S, Hosein I, Ramsoobhag K
Trinidad & Tobago

Pre-Operative Radiologic Diagnosis of Left Para-Duodenal Hernia
Bobb NJ, Maharaj R, Naraynsingh V, Rampersad F
Trinidad & Tobago

Multi-Centre Study of Popliteal Artery Aneurysms Treated with Surgery over 10 Years
Persaud SDN, Harnanan D, Harnarayan P, Ramdass J, Naraynsingh V
Trinidad & Tobago

Fragile Aorta: Replacement of Ascending Aorta for Type-A Aortic Dissection
Ramsingh R, Juman S, Rampersad R, Calderas C, Teodori G
Barbados

Traumatic arteriovenous fistulas
Harnanan D, Babootee N , Ramdass MJ, Harnarayan P, Naraynsingh V
Trinidad & Tobago

Major Lower Extremity Amputations in Trinidad & Tobago
Shah A, Islam S, Jarvis J, Richardson R, King K
Trinidad & Tobago

Bacterial Isolates and Antibiotic Susceptibility Profiles at a Burn Unit in Guyana
Rajkumar S, Maccloud L
Guyana

Human Papillomavirus and Head and Neck Squamous Cell Carcinomas
Richards D, Juman S, Mohammed W, Fundora R, Santo R, Naraynsingh C
Trinidad & Tobago

Lifestyle Practices Among Health Care Professionals in a Tertiary Hospital in Trinidad
Islam S, Saroop S, Bheem V, Harnarayan P, Dan D, Cawich SO, Naraynsigh V
Trinidad & Tobago

The importance of medical associations to the isolated surgeon
Greenidge C
St. Lucia

ABSTRACTS

SCIENTIFIC SESSION 1

THE RATE OF LAPAROSCOPIC CONVERSIONS AT PRINCESS MARGARET HOSPITAL

Bodie D, Munroe LU
Princess Margaret Hospital, Department of Surgery, Nassau, Bahamas
Email: sueandlocks@hotmail.com

BACKGROUND: To date there is limited data available on the overall conversion rate of laparoscopic to open procedure at a national or regional level. The aim of this review was to determine the rate of conversion and identify factors that may trigger conversions in the environment of the Princess Margaret Hospital (P.M.H.).

METHODS: A single centre, retrospective cohort study was carried out accessing data in the Surgical Information System at the PMH. Factors included: technical difficulties, level of experience, and training certification of the surgeon.

RESULTS: A total of 455 laparoscopic cases were performed during the period January 2016 to December 2019. Of these, 380 (83.5%) cases were performed by general surgeons. Two thirds (239, 62.9%) were performed at consultant level. The commonest procedure was the cholecystectomy (265, 69.5%). The rate of conversion was 1.84%, with commonest indication being technical difficulties. Conversion rate was higher in emergency (6, 85.7%) cases versus elective (1,14.3%).

CONCLUSIONS: The rate of conversion, quality, and variety of minimal access procedures performed during this study period appears equivalent to that reported in literature. The level of staff performing the procedure may have a significant role in these outcomes.

HIDDEN SCAR APPENDECTOMY IN GUYANA

Singh D, Ramcharan H, Rambaran N
Georgetown Public Hospital Corporation, Georgetown Guyana
Email: drohinathsingh@yahoo.com

BACKGROUND: Acute Appendicitis is the most common emergency surgical procedure performed worldwide. Historically, the open method was preferred but since its conception, the laparoscopic technique has gained popularity with most surgeons. In this retrospective case report, we aim to highlight a modification of the standard laparoscopic technique used to achieve a more cosmetic outcome in younger patients.

METHODS: A retrospective review was done for a ll procedures using the hidden scar appendectomy technique. These were patients who were young. Photos were taken on post-operative day one with the patient standard wearing minimal clothing.

RESULTS: A total of seven cases were done. All patients who had appendectomy using this modified technique were satisfied with their scars on post-operative day one and also at three weeks post-op. Intraoperatively, all the appendences were found to be inflamed.

CONCLUSIONS: This method has excellent cosmetic results and improves outcomes post operatively from patient's perspective.

BLINDNESS SECONDARY TO OPTIC NERVE ISCHEMIA AFTER PROLONGED CARDIAC ARREST

Pust GD, Kaslow A, Chatoor M, Jain S, Kateregga A, Ruiz G, Marttos A, Kaufman J, Hart V, Ginzburg E, Yeh DD, Namias N
Ryder Trauma Center, Jackson Memorial Hospital, University of Miami, Miami, United States of America
gpust@med.miami.edu

INTRODUCTION: Blindness secondary to cortical ischemia or optic nerve ischemia is a known complication after medical cardiac arrest. Successful resuscitation after traumatic cardiac arrest is rare and blindness after successful resuscitation traumatic arrest is even rarer.

REPORT OF A CASE: The patient is a 24-year old man who sustained a single gunshot wound to the left chest resulting in left axillary artery injury, hemothorax, and pulmonary laceration. On arrival to the operating room, the patient suffered cardiac arrest requiring resuscitative thoracotomy, open cardiac massage, lobectomy, and shunting of the axillary artery. Restoration of spontaneous circulation (ROSC) was achieved initially after four minutes; however, cardiac arrest recurred, requiring prolonged open-heart massage and internal defibrillation for an additional 15 minutes until permanent ROSC was achieved. The patient required subsequent extra-corporeal life support and recovered after a prolonged intensive care unit stay. His recovery is complicated by blindness secondary to ischemic optic nerve damage. Initially he was completely blind, however over the following weeks he began to distinguish light from darkness.

CONCLUSIONS: Blindness secondary ischemic optic nerve damage is a rare, but devastating complication after traumatic cardiac arrest. Further research is needed to have a better understanding of the incidence, contributing factors, pathophysiology and long-term outcome of this complication.

SCIENTIFIC SESSION 2

A REPORT OF CHEMODECTOMA

Shoogoon A, Pran L, Harnanan D
Eric Williams Medical Sciences Complex, Champs Fleurs, Trinidad and Tobago
Email: a.shoogoon@hotmail.com

INTRODUCTION: Chemodectoma is a highly vascular tumor of the neuroendocrine tissue of the carotid body. Of these chemodectomas, approximately 5-10% are malignant. They lie in close proximity to the carotid bifurcation, making resection somewhat challenging. This study reports the case of a 64 year old hypertensive female who presented with recurrent episodes of syncope.

REPORT OF A CASE: A 64-year old hypertensive with a history of syncope was referred to the vascular clinic with a computerized tomography scanning of her brain showing a 5.6mm acute ischemic lacunar infarct in the right lentiform nucleus with an incidental mass at the right carotid bifurcation. A formal CT angiogram of the brain was ordered and a 3.2 x 2.5 x 5.5 cm mass arising from the right carotid bifurcation, interposed between the right internal and external carotid arteries was noted. The impression of a carotid body paraganglioma, Shamblin type 2 was made. The patient subsequently underwent elective surgical resection using a retro-carotid dissection technique which led to a successful resection and minimal complications.
Histopathological analysis of the mass showed findings consistent with a paraganglioma with an intact capsule, no evidence of malignancy.

CONCLUSION: Shamblin II tumors at the carotid bifurcation are very risky to deal with intra-operatively and require careful planning. Energy sources are undeniable in their value in maintaining haemostasis; the harmonic scalpel which was used in this case proved to be an essential factor in our case.

ANTERIOR SKULL BASED TRAUMA

Dixon B, Daley A, Goodluck-Tyndall R, Hall D, Holness R, Jadusingh W, Pencle FK
Cornwall Regional Hospital, Montego Bay, Jamaica
Email: brad.dixon77@gmail.com

BACKGROUND: The skull base is a complex anatomic region that poses a surgical challenge for both neurosurgeons and ENT surgeons alike. Such trauma and fractures are invariably accompanied by traumatic head injury and other associated injuries which requires multispecialty involvement.

REPORT OF A CASE: A 56 year old male presented with moderate head injury after he was thrown off his motorbike. Initial CT scan revealed multiple fractures of the anterior skull base in addition to severe pneumocephalus. Patient was resuscitated in according to ATLS protocol and immediately commenced on high flow oxygen post CT. Persistence of CSF otorrhea & rhinorrhea was monitored closely throughout admission as well as any further neurological deterioration. Upon discharge, patient had resolution in pneumocephalus, a normalized GCS, and complete resolution of his CSF leak. No signs of meningism were elicited.

CONCLUSION: The main complications of anterior skull base fractures are CSF leaks and infections. As such, management should always be aimed at preventing intracranial infection and fixing the fractured site. Controversies still exist in antibiotic usage management between specialties. With current technologies, persistent CSF leaks can be repaired intradurally, extradurally or endoscopically.

PENILE DEGLOVING INJURY SECONDARY TO HAIR TORNIQUET

Dubay C, Rampersad B
Eric Williams Medical Sciences Complex, Champ Fleurs, Trinidad
Email: cididubay@hotmail.com

BACKGROUND: Hair tourniquet syndrome, a rare phenomenon, occurs when a strand of hair becomes wrapped around an appendage causing initial lymphatic and venous congestion. It can progress to arterial occlusion, ischemia, necrosis or autoamputation. The majority occur in infants, usually affecting the digits, but can occur at many other sites including the penis and labia.

REPORT OF A CASE: Our patient, a 2 year old uncircumcised male, presented with a 1 day history of 'red rash to penis,' followed by a bleeding wound of 5 hours duration. On examination, there was a circumferential degloving injury to the base of the penis, with oedema to the penis and scrotum. There was no history of trauma. After initial diagnostic confusion, including worries of non accidental injury, a diagnosis was ascertained after retrieval of nappy which contained a single strand of red maternal hair. His urethra was uninvolved. He was treated with debridement and primary repair, and recovered uneventfully.

CONCLUSIONS: Hair tourniquet can present diagnostic difficulty as human hair is very thin and easily overlooked. Additionally, re-epithelialization may occur which may obstruct the offending hair or thread. A high index of suspicion is necessary. Delayed diagnosis may result in gangrene, autoamputation, urethral transection, or urethrocutaneous fistula. A variety of treatment techniques exist, including the use of depilatory cream, unwrapping, blunt probe and incisional techniques.

CUTANEOUS METASTASIS IN RECTAL CANCER POST ABDOMINOPERINEAL RESECTION AND PULMONARY METASTASECTOMY

Johnson B, Ramlogan R, Moore I, Gamboa I, West M
Eric Williams Medical Sciences Complex, Champs Fleurs, Trinidad and Tobago
Email: iamdrjohnson@icloud.com

INTRODUCTION: Carcinoembryonic antigen is a useful tumor marker in the follow up of colorectal cancer patients after surgical therapy. Elevated levels usually suggest recurrent or metastatic disease. We present the case of a known rectal cancer patient with normal routine surveillance contrast enhanced CT imaging but occult cutaneous metastasis detected on PET CT as cause for elevated CEA levels post surgery.

REPORT OF CASE: A 66 year old ECOG1, ex smoker, diabetic, hypertensive male with history of locally advanced moderately differentiated rectal cancer post neoadjuvant chemoradiation and abdominoperineal resection was referred to our institution after surveillance CT scan 6 months post op revealed solitary lung nodule in left upper lobe. CT guided biopsy confirmed metastatic rectal cancer. Serial imaging revealed increasing size of lung lesion on 2nd line chemotherapy. Left upper lobectomy and apicectomy of left lower lobe was performed via left posterolateral thoracotomy for 5cm lung mass crossing oblique fissure invading into apical segment left lower lobe. Serial surveillance contrast enhanced CT imaging revealed no evidence of metastatic disease or local recurrence in spite of rising CEA levels 9 months post pulmonary metasectomy. A PET CT subsequently revealed a soft tissue tumor deposit within subcutaneous tissues deep to and medial to the posterior thoracotomy scar. Wide excision with clear margins confirmed metastatic rectal cancer and patient was referred for continued oncologic therapy and followup.

CONCLUSIONS: Conventional imaging may fail to detect cause of asymptomatic CEA elevations in surveillance of colorectal cancer patients. This case illustrates the selective use of PET CT to diagnose the rare phenomenon of cutaneous metastasis in rectal cancer as cause for asymptomatic CEA elevation post abdominoperineal resection and pulmonary metasectomy.

KNOWLEDGE OF BREAST CANCER IN PATIENTS DIAGNOSED WITH BREAST DISEASE

Mohammed S, Islam S, Hosein A
San Fernando General Hospital, San Fernando, Trinidad and Tobago
Email: sidiyq@gmail.com

BACKGROUND: The prevalence of breast cancer in the Trinbagonian population is rising. The objective of this study is to identify the general knowledge a newly diagnosed breast disease patient has about breast cancer and thereby identify areas in which public education may be boosted.

METHOD: All newly diagnosed breast disease patients presenting to the specialist breast clinic were administered a survey. The data was compiled using various analytical instruments and is continuously being updated.

RESULTS: Approximately half (49.6%) of the population studied had education up to a secondary school level with 57.5% having prior knowledge of breast cancer antecedent to diagnosis. The vast majority of patients (79.5%) knew about screening mammograms but only 39.8% of patients were diagnosed from screening mammograms. On average, greater than 70% of the population did not have knowledge about the basic risk factors or protective factors for breast cancer. Most patients (89.5%) understood that diagnosis at an early stage would give them a better chance of cure.

CONCLUSION: There is a deficiency of knowledge in the general population of risk factors and protective factors for breast cancer and this can be addressed by revised and improved primary health care initiatives, and introduction of information into the school curriculum. There is a question of why patients are not being picked up via screening mammograms even though most patients know about the test; this may have to be further investigated.

PRIMARY NON-CUTANEOUS MALIGNANT MELANOMA OF THE BREAST

Murray N, Hassranah D, Olivier L, DeFreitas A, Richardson R, Persad N
Sangre Grande District Hospital, Trinidad and Tobago
E-mail address: nikkitamurray91@hotmail.com

INTRODUCTION: Malignant melanoma of the breast represents 0.5% of all breast cancer cases and 5% of all malignant melanoma. It can be classified into primary cutaneous malignant melanoma, primary non-cutaneous malignant melanoma and metastatic malignant melanoma. The incidence of primary non-cutaneous malignant melanoma is rare, with few cases reported in English literature.

REPORT OF A CASE: This is a case of a 20 year-old female with a left breast mass for 3 years. The mass grew from a 2 cm lesion with no skin changes from her initial presentation to a 5cm ulcerating lesion with axillary lymphadenopathy. Core biopsy revealed a malignant melanoma of the breast, positive for Melan-A. There was radiological evidence of axillary lymphadenopathy and involvement of the Pectoralis muscle; without distant metastases. It is recommended that management of breast melanoma should include local excision and treatment of the axilla as necessary. However, due to the extensive nature of disease, this patient underwent a mastectomy, axillary vein resection with primary vein anastomosis to achieve tumour free margins, and immediate reconstruction with Transverse Rectus Abdominis Myocutaneous flap.

CONCLUSIONS: This case represents a rare clinical entity with poorly defined pathophysiology. It is the first documented case of its kind in Trinidad and Tobago.

BREAST CARCINOMA RECEPTOR EXPRESSION IN A CARIBBEAN POPULATION

Ramdass MJ, Gonzales J, Maharaj D, Simeon D, Barrow S
University of the West Indies, Trinidad, W.I.

AIM: To determine the differences in breast carcinoma receptor status between East Indians (EI) and Afro-Caribbean (AC) women in a constant environment.

METHODS: The records of the All EI and AC women presenting to the POSGH for the year 2015 were analysed. Data was collected on age, ethnicity, histologic type of breast carcinoma and the ER, PR and HER receptor status for the period. Mixed and minority races were excluded. Comparative analyses were done and relevant Chi-Square tests to determine any statistical differences.

RESULTS: There were 258 women included in the study with an age range of 28-93 with a mean of 57. There were 103 EI and 155 AC women with 88% (227) of tumours being Invasive Ductal, 9.7% being Invasive Lobular and 2.3% being DCIS. The triple negative rates were 27% (28/103) and 32% (49/155) for EI and AC respectively with no statistical difference on Chi-Square testing $p>0.05$. The ER-ve rates were 54% (56/103) and 50% (78/155), PR-ve rates 63% (65/103) and 65% (100/155) and HER-ve rates were 75% (77/103) and 82% (127/155) for EI and AC respectively.

CONCLUSION: Trinidad & Tobago is a constant environment and the patients analysed are from similar socio-economic backgrounds. Therefore, given the findings of similar receptor status in both groups in this sample. We herein conclude that there must be some other environmental factor to explain higher triple negative rates in black in women in the world data.

AN UNUSUAL CAUSE OF 'RECTAL PROLAPSE'

Mohammed S, Singh Y, Hosein A, Naryansingh V
San Fernando General Hospital, San Fernando, Trinidad and Tobago
Email: sidiyq@gmail.com

INTRODUCTION: Adult intussusception is a rare condition representing the cause of approximately 0.003% (3 of every 100,000) of hospital admissions in this population and only a small fraction of adult intussusception is attributed to the sigmoido-rectal region.

REPORT OF A CASE: A middle aged woman was admitted to our hospital due to rectal prolapse and anal bleeding from 5 days. On DRE a palpable mass was present at the anal verge and a colonoscope could not pass. CT scan demonstrated the presence of a classic sausage shaped, sigmoido-rectal intussusception. The patient underwent emergency anterior resection of rectum with stapled colo-rectal anastomosis.

CONCLUSION: With regard to operative management, recent studies recommend a selective approach to bowel resection that takes into consideration the location and pathologic characteristics of the underlying lesion. In patients older than age 60 years or in intussusceptions with colonic lesions, bowel resection following the appropriate oncologic principles is recommended given the high incidence of malignancy. Our experience lends strength to early resection without reduction.

CLINICOPATHOLOGIC PROFILE OF RECTAL CANCER IN A CARIBBEAN HOSPITAL

Sirjeusingh D, Persaud S, Hosein I, Ramsoobhag K
San Fernando General Hospital, San Fernando, Trinidad and Tobago
Email: dinelle_sirjuesingh@hotmail.com

OBJECTIVE: To document the demographic and pathological profile of renal cancer at San Fernando General Hospital, Trinidad and Tobago over a five-year period (2015-2019).

METHODS: A retrospective study analyzing all patient histologies who had a diagnosis of renal cancer with surgical treatment from 2015-2019. Data was collected on patient demographics, clinical presentation and disease pathological characteristics such as cancer size, location and grade. Data was tabulated on MS Excel and analyzed using SPSS version 21.

RESULTS: Over a 5-year period, there were 42 patients diagnosed with kidney cancer who had surgical intervention. The age ranged from 18 to 81 years with a mean age of 61 years and 67% of patients were over the age of 60. There were more males than females consisting of 57% of all the patients. Most patients presented with pain, hematuria or both. 97% of the patients had radical nephrectomy as the surgical treatment with equal distribution of right and left tumours. Clear cell carcinoma is the most common renal carcinoma with 68% followed by papillary with 15%. The majority of tumours were Fuhrman grade 2 with negative surgical margins and no lymphovascular invasion. The average maximum tumour dimension was 4.2cm.

CONCLUSIONS: This study shows that renal cancer affects a wide range of ages, mostly men with the common presentation of pain. The tumours from histology are commonly clear cell carcinoma of grade 2 with negative margins, no lymphovascular invasion and average maximum dimension of 4.2cm.

PRE-OPERATIVE RADIOLOGIC DIAGNOSIS OF LEFT PARA-DUODENAL HERNIA

Bobb NJ, Maharaj R, Naraynsingh V, Rampersad F
Eric Williams Medical Sciences Complex, Trinidad and Tobago
Email: nahmorahbobb@gmail.com

BACKGROUND: Paraduodenal hernias (PDH), although uncommon, are the most frequent type of internal hernias encountered in small bowel obstruction. They constitute approximately 1% of all small bowel obstructions, predominantly in men,with a ratio of 3:1 on the left as compared to the right side.

CASE REPORT: A 22-year old male presented with periumbilical pain and bilious vomiting. Computed tomography (CT) of his abdomen and pelvis with intravenous contrast demonstrated features congruent with that of a left PDH. The neck of the hernia sac measured 4.5cm and the inferior mesenteric vein (IMV) was seen in its anterior fold. The hernia contained dilated loops of small bowel. A small bowel series subsequently performed showed encysting of small bowel in the left upper quadrant. An open repair of the left PDH was performed.

CONCLUSIONS: The accurate diagnosis of this unusual pathology requires the surgeon to be acutely aware of the clinical significance of a left PDH and to request timely imaging. A key sign is an anteriorly displaced IMV in the neck of the hernia sac on CT. Additionally, small bowel series showing encysting of small bowel in the left upper quadrant, as demonstrated in this case, is also indicative of a left PDH.

MULTI-CENTRE STUDY OF POPLITEAL ARTERY ANEURYSMS TREATED WITH SURGERY OVER 10 YEARS

Harnanan D, Harnarayan P, Ramdass J, Naraynsingh V
Eric Williams Medical Sciences Complex, Champ Fleurs, Trinidad and Tobago.
Email: dave_harnanan@yahoo.com

BACKGROUND: Popliteal Artery Aneurysms (PAA) have a propensity for embolization, compression of adjacent structures and rupture. The management is surgical due to a previously high rate of limb loss. This study investigated clinical presentation and current management concepts in patients presenting with PAA.

METHODS: Retrospective comparison of presentation of fifteen (15) patients presenting with PAA, their demographics, management and surgical options available at three major tertiary care centers.

RESULTS: All patients were middle aged to elderly with all but one being male. Most were symptomatic, a majority of which had threatened limbs. A predominance of bilateral disease was noted. There was a small correlation to presence of intracranial aneurysms (1/15) and correlation with abdominal aortic aneurysms (3/15). Surgery ranged from arterial thrombectomy in acute cases followed by a choice of exclusion of aneurysm with bypass, aneurysm repair with inlay graft or endovascular repair. The results indicate 80% salvage rate with two early amputations. The 12 and 24 month salvage rates were 87% and 80% respectively.

CONCLUSION: Early surgical intervention especially in the acute cases can lead to good salvage rates with return to a favorable functional outcome and long term limb viability. The risk of limb loss from PAA reinforces the importance of elective management and surgical repair.

FRAGILE AORTA: REPLACEMENT OF ASCENDING AORTA FOR TYPE-A AORTIC DISSECTION

Ramsingh R, Juman S, Rampersad R, Calderas C, Teodori G
Caribbean Heart Care Medcorp, St. Clair Medical Centre, Port-of-Spain, Trinidad & Tobago.
Email: ramsinghrichard@gmail.com

INTRODUCTION: Thoracic endovascular aortic repair (TEVAR) is the standard of care for symptomatic Type B aortic dissection. When associated with primary entry tear at the aortic arch, it is necessary to augment TEVAR with debranching and bypass of the supra-aortic branches. It is rarely complicated by delayed retrograde type A aortic dissection. Clinical course despite standard of care is uncertain. This report highlights a rare complication of TEVAR and its successful management.

REPORT OF A CASE: A 64-year old chronic smoker and hypertensive male presented with crushing chest pain radiating to back. Imaging confirmed sub-acute type B aortic dissection with renal malperfusion. The cardiothoracic team performed debranching of supra-aortic vessels from arch of aorta followed by the interventional cardiology team who performed TEVAR with a covered stent graft continuing with two uncovered stents distally using the Pettitcoat technique. Imaging in outpatient clinic confirmed a chronic type A aortic dissection from the sinotubular junction to the endovascular graft. Replacement of the ascending aorta was later performed using a Dacron tubular prosthesis. The patient had an uneventful post-operative recovery with no complaints at 6-month follow-up.

CONCLUSIONS: Retrograde type A aortic dissection is an uncommon complication after TEVAR and is multifactorial. To prevent this, we recommend avoiding intimal tears with stiff wire, appropriate stent-graft sizing, and care when applying and removing aortic cross-clamp.

TRAUMATIC ARTERIOVENOUS FISTULAS

Harnanan D, Babootee N , Ramdass MJ, Harnarayan P, Naraynsingh V
Eric Williams Medical Sciences Complex, Trinidad & Tobago
Email: dave_harnanan@yahoo.com

BACKGROUND: Arterial trauma can be complicated by the development of arteriovenous fistulas (AVFs). There is variability in clinical presentation and may be life or limb threatening. This report highlights the clinical presentation of patients with traumatic AVFs throughout three major centers in Trinidad & Tobago.

METHODS: A 10-year retrospective analysis was conducted at EWMSC, POSGH and SFGH on all patients diagnosed with traumatic AVFs for the period 2010-2020. Data was collected on clinical presentation, etiology, anatomy and surgical strategy.

RESULTS: Twenty four (24) cases of arteriovenous fistula due to trauma were identified. All cases were due to penetrating trauma. One patient presented with bilateral lower limb AVFs and right heart failure and one patient had an upper limb AVF; all others occurred in the lower extremity. Presenting symptoms included pain, limb swelling, pulsatile mass, varicosities and dyspnoea. Diagnosis was confirmed using duplex ultrasound, computed tomography angiography and conventional diagnostic angiography. Sixty (60) percent of the traumatic AVFs arose from the SFA with the remainder from the PFA. Two (2) patients had endovascular repairs and 22 had open repairs. Patients were discharged within 2-14 days. There were no recurrences, limb loss or mortalities.

CONCLUSIONS: The diagnosis of traumatic AVF should be considered in patients presenting with arterial trauma. It is easily missed in the initial presentation and successful repair can be quite challenging with delayed presentations.

MAJOR LOWER EXTREMITY AMPUTATIONS IN TRINIDAD & TOBAGO

Shah A, Islam S, Jarvis J, Richardson R, King K
San Fernando General Hospital, Trinidad.
Email: aneela_779@hotmail.com

BACKGROUND: Major lower extremity amputation is defined as any amputation of the limb performed above the level of the ankle. Indications often include severe infection, ischemia, trauma and tumours. In 2002, Naraynsingh et al described the rate and indications of major lower limb amputations at a single surgical centre in Trinidad and Tobago over a 2 year period, which differed from other parts of the world. This study aims to provide an update on the rate and indications of major lower limb amputation in Trinidad and Tobago over a 7 year period.

METHODS: A retrospective review of major lower limb amputations was performed of at three general hospitals in Trinidad and Tobago from January 2012 to December 2018. Demographics included patients' age, gender and comorbid status.

RESULTS: 807 males and 625 females underwent major lower limb amputations, with a mean age of 75.7 years. 42.5% (415) of patients were of East Indian descent, comprising the majority of ethnic distribution. Diabetic foot complications comprised the majority of indications for amputations in this study.

CONCLUSIONS: The results of this study show that diabetes and associated peripheral vascular disease continue to be a major risk factor for lower limb amputations, which negativlewy impacts the overall health of our society. We advocate for continued education on preventative foot care in diabetics and on lower limb complications associated with diabetes mellitus.

BACTERIAL ISOLATES AND ANTIBIOTIC SUSCEPTIBILITY PROFILES AT A BURN UNIT IN GUYANA

Rajkumar S, Maccloud L
Burns Care Unit, Georgetowm Public Hospital Corporation, Georgetown, Guyana
Email: shiloraj@gmail.com

BACKGROUND: Infection is a major cause of mortality and morbidity among burn patients. An effective measure to reduce infection is routine monitoring of bacterial infection and antimicrobial susceptibility patterns at the burn unit. This will help to create a burn centre-specific empirical antibiotic therapy protocol.

METHODS: A retrospective, descriptive study was conducted at the Georgetown Public Hospital Corporation, Burn Unit between January 2015 to January 2019. Data regarding bacterial culture isolates, antimicrobial susceptibility spectrum, and the number of burn patients diagnosed with sepsis were collected.

RESULTS: There were 104 patients with positive bacterial cultures, with the isolates changing continuously between Pseudomonas Aeruginosa (23%), MRSA (15%), Acinetobacter spp (14%), Klebsiella pneumonia (13%), Coagulase Negative Staphylococcus (9%), Staphylococcus aureus (6%), Enterobacter spp (6%), Proteus (4%), Enterococcus spp (3.5%), Escherichia Coli (2.6%) and Providencia spp, Chromobacterium spp, Citrobacter spp and Morganelli spp each being (0.8%). Fourteen patients were diagnosed with sepsis (32%). Two major sepsis-causing bacteria were P. aeruginosa (33.3%) and K. pneumoniae (28.9%).

CONCLUSIONS: Bacterial isolates in the Burn Care Unit generally remained constant. The isolateds varied between Klebsiella pneumonia, Pseudomonas aeruginosa, Staphylococcus spp. and Acinetobacter spp. The most commonly seen isolates were Pseudomonas aeruginosa and Methicillin Resistance Staphylococcus Aureus. There was no significant change in the antibiotic susceptibility over time.

HUMAN PAPILLOMAVIRUS AND HEAD AND NECK SQUAMOUS CELL CARCINOMAS

Richards D, Juman S, Mohammed W, Fundora R, Santo R, Naraynsingh C
Eric Williams Medical Sciences Complex, Trinidad & Tobago
Email: david.s.richards23@gmail.com

BACKGROUND: The link between Human Papillomavirus (HPV) and Head and Neck Squamous Cell Carcinoma(HNSCC) has been well established over the last two decades. HPV causes over expression of certain cellular antigens, which have been studied extensively in the pathogenesis of cervical cancer(1). The aim of this study is to determine if HPV infection is present in head and neck squamous cell cancer in a single centre.

METHODS: The Pathology Department of Eric Williams Medical Sciences Complex archived database was searched for patients with a positive diagnosis of HNSCC within the period from January 2012 to June 2019. Samples were retrieved from the Pathology lab archived storage. All cases was examined by the pathologist and histologically classified. Immunohistochemistry (IHC) antigen testing was done with an antigen kit (Monoclonal antibody p16-INK4 (MX007). Twenty-one cases were tested for this pilot study. A case of carcinoma of the uterine cervix was used as positive control and a case of a known HPV-negative well-differentiated tongue SCC was used as negative control.

RESULTS: Staining was performed on twenty-one (21) samples. Out of the twenty one (21) samples tested four (4) were female, sixteen (16) were male, six (6) came back positive for HPV infection determined by p16INK4a testing and out of this six (6), three (3) were female. 75% of the female patients tested in this study were positive for HPV. Though the sample is small the distribution of the cases and the positive HPV rate is comparable to most documented papers.

CONCLUSIONS: Human Papilloma Virus associated HNSCC is as prevalent in the Caribbean setting as it is in the US and other geographical regions as reflected in the literature. The overwhelming positive result from this pilot study of such a small sample size provides the impetus to developing further studies and the routine HPV testing of HNSCC patients' samples with IHC for p16 antigen status.

LIFESTYLE PRACTICES AMONG HEALTH CARE PROFESSIONALS IN A TERTIARY HOSPITAL IN TRINIDAD

Islam S, Saroop S, Bheem V, Harnarayan P, Dan D, Cawich SO, Naraynsigh V
San Fernando Teaching Hospital, San Fernando, Trinidad and Tobago
Email: sabrina_saroop@hotmail.com

BACKGROUND: According to the Global Burden of Disease (GBD) study, in 2015, >600million adults and >100million children worldwide are affected by obesity. 23% of the Caribbean and Latin American population are obese. The highest rates of obesity are in Barbados (36%) and Trinidad & Tobago and Antigua & Barbuda tied at 31%. The aims of this study were: (1) to identify the prevalence of obesity amongst health care professionals and (2) to identify the personal strategies used by health care professionals to achieve a healthy weight.

METHODS: A cross-sectional survey was done amongst health care professionals at the SFGH. Data collected over a 3 year period and included demographics, BMI, dietary and exercise practices, personal views on effectiveness of weight loss strategies.

RESULTS: 200 health professionals were surveyed with 61% being female. 85% of respondents were between 20-39yrs. 29.5% of all surveyed were obese. 70% claim to be actively trying to lose weight or stay fit with a diet and or exercise routines. There is however a high rate of consumption of fast foods and processed snacks.

CONCLUSIONS: Strategies should be devised/ employed to assist the workforce with achieving healthier weight goals and lifestyle practices. There is a direct correlation between obesity and many MSK and mental health conditions, which are two of the major reasons for work-related absence and work-related injuries in healthcare. Therefore, the sustainability and efficacy of the workforce is directly impacted by the prevalence of obesity.

THE IMPORTANCE OF MEDICAL ASSOCIATIONS TO THE ISOLATED SURGEON

Greenidge C,
Tapion Hospital, St. Lucia

Non-campus territories generally have fewer sub-specialists and investigative and therapeutic resources. Caribbean medical associations bring resources available in the wider Caribbean and beyond much closer to the 'isolated' surgeon. This presentation discusses how these associations both formal and informal can play an important role

BULLETIN:

William "Bill" Aiken promoted to the rank of Professor of Urology by the University of the West Indies

The Caribbean College of Surgeons extends our congratulations to William (Bill) Aiken on his recent promotion to the rank of Professor of Urology at The University of the West Indies. Professor Aiken compled a M.B.B.S. Degree in 1989 and a Post-Graduate Degree in Urology in 1998. He became a Fellow of The Royal College of Surgeons of Edinburgh in 1995 and was awarded a Commonwealth Scholarship in 1996 in Urology at the Western General Hospital in Edinburgh, Scotland. He is the first graduate of The UWI's Doctor of Medicine Programme in Urology and was mentored by Professor L. Lawson Douglas.

Professor Aiken joined the academic staff at The UWI Mona Campus in 1998 and two years later was appointed a lecturer in Urology. During his tenure as DM Supervisor, ten persons successfully completed urological training and have filled Consultant posts in the English-speaking Caribbean.

Professor Aiken has served as President of the Jamaica Urological Society, the Caribbean Urological Association and is the Immediate Past President of the Association of Surgeons in Jamaica. He currently serves on the Medical Council of Jamaica and was recently made an International Surgical Advisor for Jamaica by the Royal College of Surgeons of Edinburgh.

The promotion to the rank of Professor recognizes his academic achievements and leadership roles in Surgical Societies. He has 52 peer-reviewed full publications and over 40 Abstracts in Scientific Journals. He has received The UWI Mona Principal's Research Award on three occasions, been awarded the Association of Surgeons in Jamaica's prize for Best Surgical Research at the Faculty of Medical Science's Research Day and has been invited by the American Urological Association and the Société Internationale d'Urologie (SIU) to judge podium presentations on prostate cancer.

Professor Aiken is a Fellow of the Caribbean College of Surgeons, the American College of Surgeons, and the Royal College of Surgeons of Edinburgh, and is also an Associate Editor for the Journal of the Caribbean College of Surgeons.

CARIBBEAN COLLEGE OF SURGEONS

www.caribbeancollegeofsurgeons.com
P O Box 41W, Worthing, Christ Church, Barbados
Email: collsurg@caribsurf.com

President: C. Wilkinson
Past President: R Jonnalagadda
Vice President: S.O. Cawich
Secretary: C. Greenidge
Treasurer: C. Warner
Council Members: S. Rajkumar, A. Baker, N Bascombe, W. Francis, D. Dan

INSTRUCTIONS FOR AUTHORS

The Journal is published by the Caribbean College of Surgeons to provide a forum through which surgical experiences and scientific research can be shared between practitioners across the Caribbean.

The Journal seeks to publish data aimed at clinical practice in the diverse Caribbean healthcare environments that often differs from those in Developed countries. Our aim is to make a meaningful impact in surgical practice for the Caribbean.

The Journal covers all medical disciplines and basic research to promote the understanding of the pathophysiologic basis, treatment and prevention of diseases in the region.

The Journal publishes original scientific research, reviews, commentaries, viewpoints, conference proceedings and case reports. All submissions are peer reviewed by two independent reviewers. Authors are given opportunities to respond to reviewers' comments and the final decisions are made by the Editor in Chief.

The authors bear professional and ethical responsibilities in publishing.

AUTHORSHIP

- Persons who directly contributed to the intellectual content of the paper should be cited as authors if they meet the following criteria: (1) conceived and planned the work that led to the paper, (2) wrote the paper or took part in the revision process and (3) approved the intellectual content in the final version.
- A statement disclosing the roles of each author with respect to the above criteria must be given.

INFORMED CONSENT

- There should be no identifying information included in the text, images, figures or photographs that form the manuscript, unless it is essential for scientific purposes. In

this case, the patient or legal guardian must provide written informed consent for publication.
- The Caribbean College of Surgeons reserves the right to reject or withdraw published articles if informed consent has not been obtained.

ETHICAL RESPONSIBILITIES
- The authors must confirm in a written statement that the study was reviewed and approved by the local Institutional Review Board.
- The authors must confirm in a written statement that all material relating to human investigations and animal experiments conforms to standards in accordance with the Declaration of Helsinki.
- The Caribbean College of Surgeons reserves the right to reject or withdraw published articles if ethical standards have not been met and/or informed consent has not been obtained.

CONFLICT OF INTEREST
- Each author must disclose financial interests, personal commitments and/or competing interests that may represent actual or potential conflicts of interest that might bias their work.
- The Caribbean College of Surgeons reserves the right to reject or withdraw published articles if any actual or potential conflict of interest exists.

Please note the following instructions for preparation of manuscripts:

COVERING LETTER

Please submit a cover letter for each manuscript. The cover letter should include:
- A statement on the authorship and each author's contribution to the manuscript
- A disclosure statement concerning conflicts of interest
- Confirmation that the manuscript has only been submitted to the JCCS and has not been previously published or being considered for publication elsewhere
- Confirmation that the manuscript contains original content
- Corresponding author's full name, mailing address, telephone number and email address.

MANUSCRIPT COMPILATION

The manuscript should be arranged in the following order:

(a) Title Page
(b) Abstract
(c) Background
(d) Methods
(e) Results
(f) Discussion
(g) Conclusion
(h) Acknowledgements
(i) References
(j) Tables and Figures

- The manuscript should be submitted using British English
- The manuscript should be double spaced, with lateral margins of 1.5cm. The text should be prepared with Microsoft Word using Times New Roman at 12 Font.

- Headings should be positioned flush with the left margin and in sentence case. First-level head ings are capitalized and **BOLDFACE**. The second level headings are capitalized and in ***ITALICS***.
- Use SI units only throughout the manuscript
- Limit abbreviations to those that are absolutely necessary. The abbreviation must be defined and in parentheses the first time it is used. Abbreviations must not be used at the commencement of a sentence.
- It is preferable to use only generic names for all drugs throughout the manuscript. However, a pro prietary drug name can be used if the generic name and manufacturer is identified in parentheses.
- The name and location of manufacturers of equipment and instruments must be given in parentheses in the text.

- Please observe the following word limits:
- Letters to the Editor: 500 words
- Book Review: 800 words
- Case Report: 1500 words
- Original Articles: 3000 words
- Review Articles: 3000 words

TITLE PAGE

- The title of the manuscript should be in bold font in title case and centered at the top of the title page. The title should be concise and reflect the content of your manuscript. You should avoid abbre viations in the title.
- List all authors without their qualifications. The authors should be listed in the order they are to ap pear in the published article.
- Identify each author's affiliation and contact details using superscript numbers
- Clearly identify the corresponding author including affiliations and contact details.
- Provide 3-5 keywords for indexing

ABSTRACT

- A structured abstract should be provided. The abstract should not exceed 250 words
- Abstracts should be prepared using Times New Roman as the font; size 12; regular style; sin gle-spaced (1.0). Please ensure that left and right margins are 1.5cm in width.
- The abstract should be structured with the following sections:

TITLE: Use bold type. Do not use abbreviations
AUTHORS: Begin on a new line two spaces below title. Use italics. List authors' surnames followed by initials of first names. Do not use full stops after initials. Omit degrees, titles and institutional appointments.
INSTITUTION: Begin on a new line immediately below Authors. Use italics. List institute(s) where work originated, city and country.
EMAIL ADDRESS: The corresponding author's email should appear in the next line.
BACKGROUND: State the main objective/ research question/hypothesis of the study.

METHODS: Briefly describe the design of the study and how it was conducted indicating study population, sampling, procedures and measurements.

RESULTS: Only the main results should be presented, with an indication of variability (e.g. SD) and precision of comparisons (e.g. 95% confidence intervals) where appropriate. Statements such as "results will be discussed" or "data will be presented" will not be accepted.
CONCLUSIONS: Limit the conclusions only to those directly supported by the results. Be as clear and specific as possible.

BACKGRIOUND

- This section should be short – one or two paragraphs – and is used to state the existing data on your topic. It is also used to introduce the main objective/ research question/hypothesis of your study.

METHODS

- A detailed description of the study design should be presented, including definitions, descriptions of inclusion and exclusion criteria, calculations of sample size and methods of sampling. There should also be a detailed discussion of the methods used for statistical analyses and the statistical software used.

RESULTS

- The results of your study are presented in this section in a clear and concise manner. Please include details of statistical analyses, where relevant.

DISCUSSION

- This section is used to provide a synopsis of the findings of your work. This section should discuss mechanisms and explanations of your findings as well as comparisons to other published studies.
- Any relevant limitations of your study should be presented and discussed at this stager. A statement on the methods used to minimize limitations and/or compensate for these limitations is required.
- You are encouraged to include comments and viewpoints related to the findings.

CONCLUSIONS

- A clear conclusion that is directly supported by your results should be presented.

ACKNOWLEDGEMENTS

- This section is used to acknowledge contributors who may have provided support but do not meet the criteria to be listed as authors.
- Any source of financial support should be included in this section.

REFERENCES

- References should be numbered in the order in which they appear cited in the body of the manu script.
- Please use Arabic numbers to list the references.

- Each reference should appear on a separate line using singe spacing.
- The references should be formatted in Vancouver style.
- List the authors' names with the surname appearing first. No commas should be used after the surname. After a single space list the abbreviations of the authors' given names, without fullstops. A follows the last initial of the author's given names.
- If there are more than 6 authors, list the first 6 authors followed by "et al".
- Use official abbreviations for journal names, if available. The journal name should be in italics and is followed by a fullstop.
- List the year followed by a semi-colon. After a single space, the journal issue should be listed with volume numbers in parentheses, followed by a colon. The page numbers appear next followed by a full stop.
- Do not use citation manager software to compile your references for the final submitted version.
- Please see the following examples:
  Brown J, Black B, Wilson F. An example of referencing for the Caribbean College of Surgeons. J Carib Coll Surg. 2019;1(1):25-30.

FIGURES AND TABLES

TABLES
- Each table should have a short descriptive title.
- Tables are listed in the order that they are quoted in the manuscript, using Arabic numbers.
- Tables should be prepared in Microsoft word format using regular font 12 type
- Each table should have a caption / legend to describe its content appearing immediately below the table.

FIGURES
- Figures should be submitted in JPEG format or TIFF format.
- Any figure submitted should have a minimum resolution of 300 DPI
- Figures should be clearly labeled with arrows and/or letters
- Each figure should be accompanied by a caption/legend that appears immediately beneath the figure

CARIBBEAN HEART CARE MEDCORP LTD.

"CARING FOR CARIBBEAN HEARTS"

Your Most Trusted Heart Care Partner, For Life

CELEBRATING OVER 27 YEARS

WHO WE ARE:

- CHCm, with over 27 years of experience, has proven to be an excellent full-service Cardiac and Vascular Care Centre, with one of the best Heart Surgery Units in the world.
- We are pioneers of the **24HR HEART ATTACK UNIT** which offers life-saving procedures, such as Angioplasty and other advanced Cardiovascular Services.
- With an **EXPERT TEAM** that is **ALWAYS READY,** we continue to be one of the most affordable in the region.

OUR SERVICES:

- **24HR CARDIAC SURGERY**
- **24HR INTERVENTIONAL CARDIOLOGY & CARDIAC CATHETERIZATION**
- **VASCULAR AND ENDOVASCULAR SURGERY**
- **ELECTROPHYSIOLOGY & DEVICES**
- **INTERVENTIONAL RADIOLOGY & NEURORADIOLOGY**
- **STRUCTURAL HEART DISEASE**
- **ECHOCARDIOGRAPHY & STRESS TESTING**
- **OTHER ELECTIVE PROCEDURES**

Put Your HEART in the Hands of EXPERTS

24HR HEART ATTACK UNIT

EMERGENCY 628-HART (4278)

SURGERY & CARDIOLOGY SERVICES
18 Elizabeth Street, St.Clair
Port-of-Spain, Trinidad. W.I.
1 (868) 628-6674/ 5978
1 (868) 628-1451 Ext. 302

SURGERY SERVICES
Eric Williams Medical Sciences Complex
Mt. Hope. Trinidad. W.I.
1 (868) 645-1712
1 (868) 645-2640 Ext. 2751

info@cheartcare.com
www.cheartcare.com
caribbean heart care medcorp
caribbean_heart_care_medcorp